

Case Reported for Iatrogenic Cystectomy During Cesarean Delivery

Alahmadi M* and Ghazi AA

Members of the Neurourology Promotion Committee of the ICS, Saudi Arabia

*Corresponding author:

Muhammad Alahmadi,
Members of the Neurourology Promotion Committee
of the ICS, Saudi Arabia, Tel: 966544666707;
E-mail: mu7ammad87@icloud.com

Received: 20 Dec 2022

Accepted: 17 Jan 2023

Published: 27 Jan 2023

J Short Name: JJGH

Copyright:

©2023 Alahmadi M, This is an open access article distributed under the terms of the Creative Commons Attribution License, which permits unrestricted use, distribution, and build upon your work non-commercially.

Citation:

Alahmadi M. Case Reported for Iatrogenic Cystectomy During Cesarean Delivery. J Gastro Hepato. 2023; V9(15): 1-4

Keywords:

Cesarean delivery; Ureterostomy; Cystotomy

1. Abstract

Bladder injury is well known complication during Cesarean Delivery (DC). We describe a case of 28 year old woman, who presented in labor. An emergency DC and hysterectomy were done to control bleeding. It was complicated by and inadvertent cystotomy. Urine diverted immediately by. After five months an Augmentation Iliocystoplasty, bilateral ureteric re-implant and abdominal catheterizable stoma were done.

2. Introduction

Most common complication of pelvic surgery is urologic injury. Bladder injury is the most frequently injured organ during pelvic surgery [1].

Iatrogenic bladder injury is a reported complication that need caution when performing pelvic and/or abdominal retroperitoneal surgeries. CD is a procedures that carry low risk for bladder injury, with incidence ranging from 0.0016% to 0.94% [2].

3. Case Presentation

A 28 year old pregnant lady with previous 2 children whom delivered by CD. She was in 36 gestational age when she presented in labor. An emergency CD. It was complicated with bleeding and hysterectomy done to control it. Obstetrician called urologist after notice Foley's catheter balloon in the surgical field.

On intraoperative findings: entire bladder body and lower ureters were removed with the uterus. Only bladder neck and part of trigon remained (Figure 1). As immediate management, both ureteric edges were refreshed and bilateral cutaneous ureterostomy were done to anterior abdominal wall.

Postoperative: course went smoothly and urine collecting in urostomy bag.

Patient was referred to our institute and counseled for neobladder vs augmentation with catheterizable continent abdominal stoma and ureteral re-implant. Patient serum creatinine was 61.5 umol/L . CT urogram done (Figure 2). showed normal excretion of both kidneys with no hydronephrosis.

Five months after CD and cystectomy; midline lower abdominal laparotomy was done. Small bladder with volume about 40 cc. It was opened from the upper part and multiple incision were done to widen the bladder opening. Bilateral ureteral re-implant done to native bladder. The appendix used to create catheterizable continent stoma to right iliac fossa and anastomosis done to native bladder. About 45cm of terminal ilium proximal to ileocecal junction used to for iliocystoplasty.

Postoperatively: patient started orally gradually from first day. Ureteric catheters and drain were removed by the end of first week. Daily manual gentle wash were done to remove mucus. Cystogram (Figure 3) done three weeks after surgery and no leak. Urethral and suprapubic catheter removed and she start using 10 Fr. catheter through stoma.

Follow up: Patient could urinate with minimal residual urine for 3 months. Then residual urine increase gradually. Currently she could not urinate and using catheter to empty her bladder every 6 to 8 hours. She is using catheterization through her urethra and stop using abdominal stoma and it obliterated. Patient followed for 16 Months. No UTI, hematuria. She is doing catheterization through her urethra without difficulty every 6-8 hours and no leak in between. Serum creatinine 61 umol/L. Ultrasound showed no hydronephrosis.

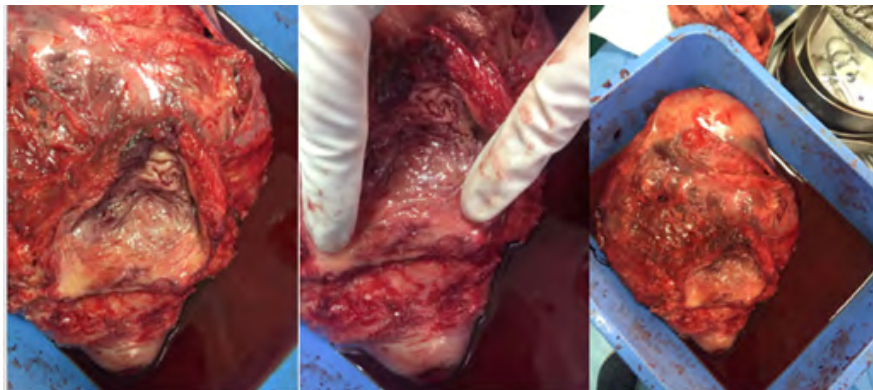


Figure 1: Ureteric orifices (red arrow). Bladder body (blue star)

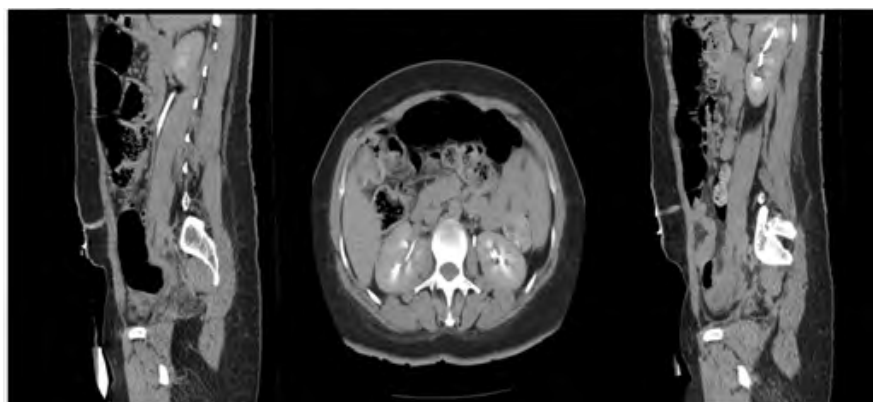


Figure 2: CT urogram 5 months after CD and cystectomy

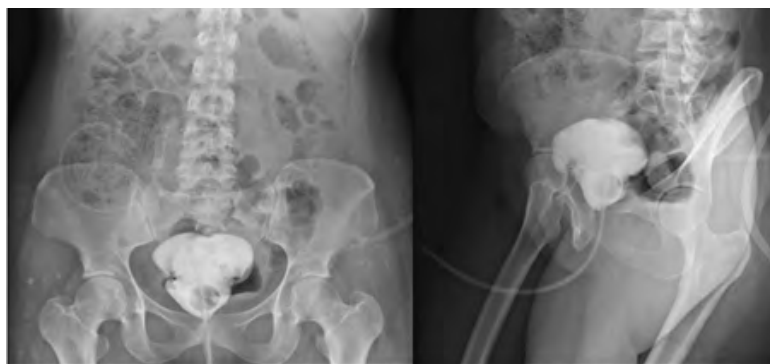

Figure 3: Cystogram 3 weeks after augmentation cystoplasty

4. Discussion

To our knowledge this is 1st case reported for iatrogenic cystectomy during CD. Iatrogenic bladder injury can happen during open, laparoscopic, endoscopic urological or abdominal surgery. CD one of common procedure associated with bladder injury. The incidence of bladder injury during cesarean section 0.44% [3].

Bladder injury during CD was reported higher in multipara, previous operation, emergency CD [4]. 41.2% of bladder injuries occurred in primary CD comparing to repeat CD 58.5% [3]. Phipps et al. and Rahman et al. demonstrated that the incidence of incidental cystotomy was three times higher in women who had a previous cesarean delivery (0.81% vs. 0.27%, $P = .0014$) [3,4].

Bladder injury more likely to occur during emergency comparing to elective CD 31% to 11% respectively. Incidence of bladder inju-

ry higher if trial of normal delivery progress to second stage 83% versus 61% if not. Uterine rupture associated with 14% of bladder injury [4]. No statistical significant of age of patient or body mass index [4].

In this catastrophe case, only 10-15% left from the bladder. Goal of management was to restore micturition function by have adequate bladder capacity with low intravesical pressure and no urinary incontinence. Patient was offered neobladder and bilateral ureteral re-implant and continent catheterizable stoma.

Augmentation cystoplasty can be offered for neurological disorders such as spinal cord injury [5], multiple sclerosis [6], myelodysplasia [7] when other treatment have failed. Also, it is an option to increase bladder capacity for small bladder capacity due to congenital bladder anomalies such as cloacal exstrophy, epispadias and posterior urethral

valves [8,9,10]. Other rare indication of AC includes post-radiotherapy cystitis, cystitis following intravesical or systemic chemotherapy, schistosomiasis, tuberculosis and interstitial cystitis[11,12] .

Augmentation cystoplasty is morbid operation associated with early complications includes cardiovascular, thromboembolic, respiratory, gastrointestinal complications and wound infection [13]. The mortality rate was up to 2.7%. Late complications include metabolic disturbance characterized by hyperchloremic acidosis [14,15] and deterioration of renal function at least by 15% of [16]. One study showed recurrent bacteriuria rate of 75%, but only a 20% are troublesome UTI [17], Bladder stones is the most common indication for reoperation reach up to 40% [18,19]. Spontaneous bladder perforation is a rare complication. It can happen if catheterization ignored by the patient and mortality reach to 23–25% [20]. The risk of malignancy in augmented bladder reported up to 1.2% [21,22]. Using the terminal ileum can lead to bile acid malabsorption, diarrhea and fat malabsorption [23].

Spontaneous voiding after augmentation cystoplasty achieved by abdominal straining to increase abdominal pressure with or without Credé maneuver, with simultaneous relaxation of the pelvic floor [24]. Patient should be council for possibility of intermittent catheterization before operation. It vary from 26% to 100%. Generally it higher in neurogenic group and increase with time [25-27]. Greenwell et al.(2001) reported a 60% intermittent catheterization rate in neuropathic patients compared with 6% in idiopathic patients.[17] .

Continent abdominal stomas can be done if urethral not able to catheterized like urethral stricture, urethral loss, sensitive urethra or if bladder neck reconstruction done. The main indication for revision was stenosis and inability to catheterize, followed by leakage.

References

1. Lee JS, Choe JH, Lee HS, Seo JT. Urologic Complications Following Obstetric and Gynecologic Surgery. *Korean J Urol.* 2012; 53(11): 795–799.
2. Aghaways I, Bapir R, Hawrami TA, Thahir NM, Hassan MAAK, Hassan KMS. Conservative management of delayed presentation of intraperitoneal bladder rupture following caesarean delivery: A case report. *Int J Surg Case Rep.* 2019; 59: 31–34.
3. Rahman MS, Gasem T, Al Suleiman SA, Al Jama FE, Burshaid S, Rahman J. Bladder injuries during cesarean section in a university hospital a 25 year review. *Arch Gynecol Obstet.* 2009; 279: 349–52.
4. Phipps MG, Watabe B, Clemons JL, Weitzen S, Myers DL. Risk factors for bladder injury during cesarean delivery. *Obstet Gynecol.* 2005; 105: 156–60.
5. Khastgir J, Hamid R, Arya M, Shah N, Shah PJ. Surgical and patient reported outcomes of ‘clam’ augmentation ileocystoplasty in spinal cord injured patients. *Eur Urol.* 2003; 43: 263–9.
6. Zachoval R, Pitha J, Medova E, Heracek J, Lukes M, Zalesky M, et al. Augmentation cystoplasty in patients with multiple sclerosis. *Urol Int.* 2003; 70: 21–6.
7. Medel, R, Ruarte, AC, Herrera, M, Castera, R, Podesta, ML. Urinary continence outcomes after augmentation ileocystoplasty as a single surgical procedure in patients with myelodysplasia. *J Urol* 2002; 168: 1849– 52.
8. Bhatnagar V, Dave S, Agarwala S, Mitra DK. Augmentation colcystoplasty in bladder exstrophy. *Pediatr Surg Int.* 2002; 18: 43–9.
9. Surer I, Ferrer FA, Baker LA, Gearhart JP. Continent urinary diversion and the exstrophy-epispadias complex. *J Urol.* 2003; 169: 1102–5.
10. Youssif M, Badawy H, Saad A, Hanno A, Mokhless I. Augmentation ureterocystoplasty in boys with valve bladder syndrome. *J Pediatr Urol.* 2007; 3: 433–7.
11. De Figueiredo AA, Lucon AM, Srougi M. Bladder augmentation for the treatment of chronic tuberculous cystitis. Clinical and urodynamic evaluation of 25 patients after long term follow-up. *Neurourol Urodyn.* 2006; 25: 433–40.
12. Shawket TN, Muhsen J. Treatment of bilharzial-contracted bladder by ileocystoplasty or colcystoplasty. *J Urol.* 1967; 97: 285–7.
13. Greenwell TJ, Venn SN, Mundy AR. Augmentation cystoplasty. *BJU Int.* 2001; 88: 511–25.
14. Khoury JM, Timmons SL, Corbel L, Webster GD. Complications of enterocystoplasty. *Urology.* 1992; 40: 9–14.
15. McDougal WS. Metabolic complications of urinary intestinal diversion. *J Urol.* 1992; 147: 1199–208.
16. Kuss R, Bitker M, Camey M, et al. Indications and early and late results of intestinocystoplasty: a review of 185 cases. *J Urol.* 1970; 103: 53–63
17. Greenwell TJ, Venn SN, Mundy AR. Augmentation cystoplasty. *BJU Int.* 2001; 88: 511–25.
18. Biers SM, Venn SN, Greenwell TJ. The past, present and future of augmentation cystoplasty. *BJU Int.* 2012; 109: 1280–93.
19. Obermayr F, Szavay P, Schaefer J, Fuchs J. Outcome of augmentation cystoplasty and bladder substitution in a pediatric age group. *Eur J Pediatr Surg.* 2011; 21: 116–9.
20. Couillard DR, Vapnek JM, Rentzepis MJ, Stone AR. Fatal perforation of augmentation cystoplasty in an adult. *Urology.* 1993; 42: 585–8.
21. North AC, Lakshmanan Y. Malignancy associated with the use of intestinal segments in the urinary tract. *Urol Oncol.* 2007; 25: 165–7.
22. Soergel TM, Cain MP, Misseri R, Gardner TA, Koch MO, Rink RC. Transitional cell carcinoma of the bladder following augmentation cystoplasty for the neuropathic bladder. *J Urol.* 2004; 172: 1649–51.
23. Hofmann AF, Poley JR. Role of bile acid malabsorption in pathogenesis of diarrhea and steatorrhea in patients with ileal resection. I. Response to cholestyramine or replacement of dietary long chain triglyceride by medium chain triglyceride. *Gastroenterology.* 1972; 62: 918–34.
24. Strawbridge LR, Kramer SA, Castillo OA, Barrett DM. Augmentation cystoplasty and the artificial genitourinary sphincter. *J Urol.* 1989; 142: 297–301.
25. Whitmore WF, 3rd, Gittes RF. Reconstruction of the urinary tract by cecal and ileocecal cystoplasty: Review of a 15-year experience. *J Urol.* 1983; 129: 494–8.

26. Kreder KJ, Webster GD. Management of the bladder outlet in patients requiring enterocystoplasty. *J Urol.* 1992; 147: 38–41.
27. Lockhart JL, Bejany D, Politano VA. Augmentation cystoplasty in the management of neurogenic bladder disease and urinary incontinence. *J Urol.* 1986; 135: 969-71.